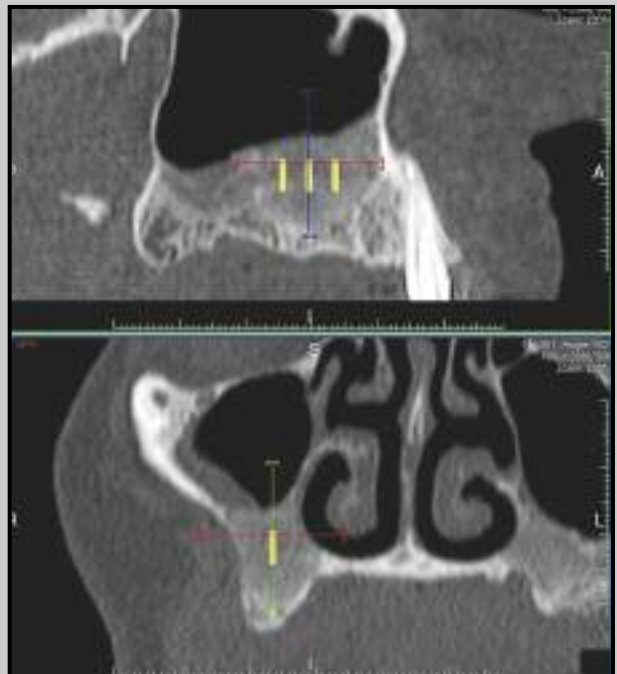
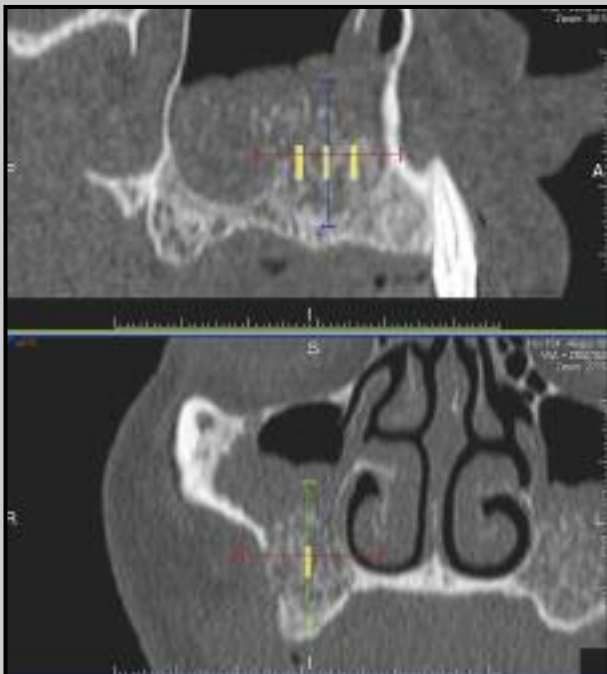
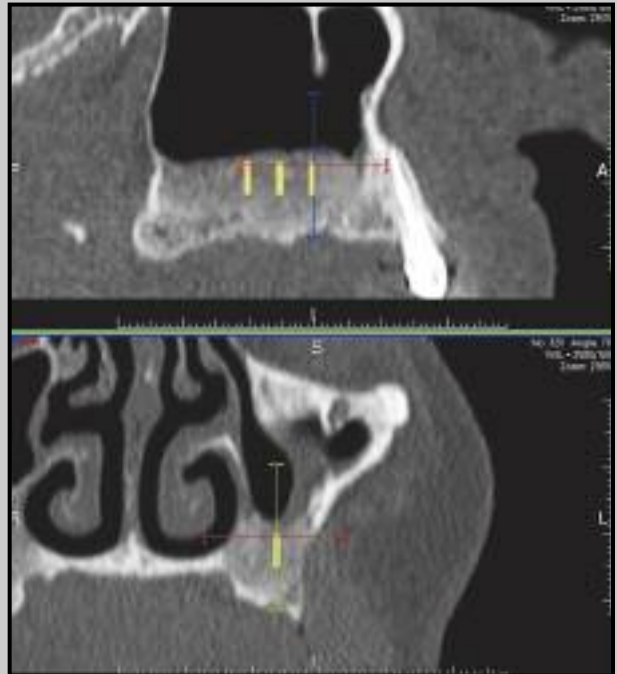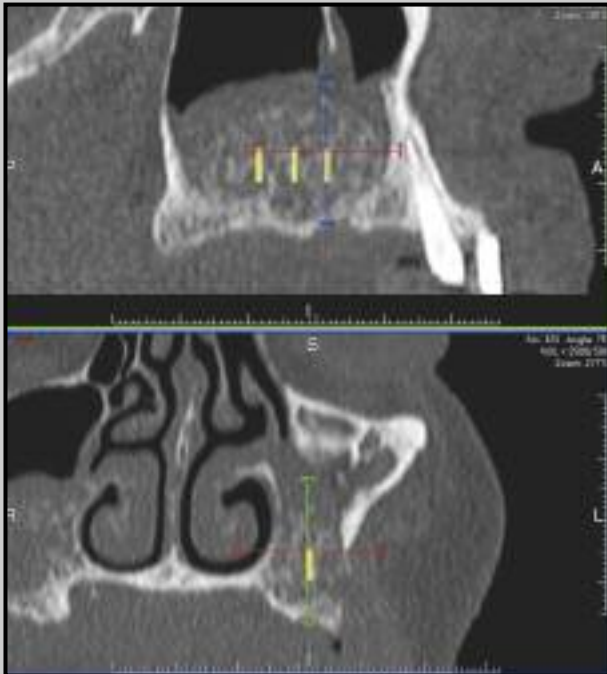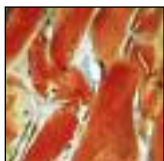Maxillary Sinus Augmentation Using Recombinant Bone Morphogenetic Protein-2/Acellular Collagen Sponge in Combination with a Mineralized Bone Replacement Graft: A Report of Three Cases



Dennis P. Tarnow, DDS¹/Stephen S. Wallace, DDS²
Stuart J. Froum, DDS¹/Alessandro Motroni, MS³
Hari S. Prasad, BS, MDT⁴/Tiziano Testori, MD, DDS, FICD⁵

The objective of the following case reports was to assess whether mineralized bone replacement grafts (eg, xenografts and allografts) could be added to recombinant human bone morphogenetic protein-2/acellular collagen sponge (rhBMP-2/ACS) in an effective manner that would: (1) reduce the graft shrinkage observed when using rhBMP-2/ACS alone, (2) reduce the volume and dose of rhBMP-2 required, and (3) preserve the osteoinductivity that rhBMP-2/ACS has shown when used alone. The primary outcome measures were histomorphometric analysis of vital bone production and analysis of serial computed tomographic scans to determine changes in bone graft density and stability. Over the 6-month course of this investigation, bone graft densities tended to increase (more so with the xenograft than the allograft). The increased density in allograft cases was likely the result of both compression of the mineralized bone replacement graft and vital bone formation, seen histologically. Loss of volume was greater with the four-sponge dose than the two-sponge dose because of compression and resorption of the sponges. Vital bone formation in the allograft cases ranged from 36% to 53% but, because of the small sample size, it was not possible to determine any significant difference between the 5.6 mL (four-sponge) dose and the 2.8 mL (two-sponge) dose. Histology revealed robust new woven bone formation with only minimal traces of residual allograft, which appeared to have undergone accelerated remodeling or rhBMP-2-mediated resorption. (Int J Periodontics Restorative Dent 2010;30:139–149.)

¹Private Practice, New York, New York, USA.

²Private Practice, Waterbury, Connecticut, USA.

³Director, Applied Medical Imaging Research Group, Milan, Italy.

⁴Senior Research Scientist, Hard Tissue Research Laboratory, University of Minnesota, Minneapolis, Minnesota, USA.

⁵Head, Section of Implant Dentistry and Oral Rehabilitation, Department of Odontology, Galeazzi Institute, IRCCS, University of Milan, Milan, Italy.

Correspondence to: Dr Stephen S. Wallace, 140 Grandview Avenue, Waterbury, CT 06708; fax: 203-573-0773; email: sswdds.sinus@sbcglobal.net.

Maxillary sinus augmentation has proven to be a predictable way to correct deficiencies in alveolar bone height and allow for implant placement with good predictability. Evidence-based reviews have shown positive outcomes using a broad range of grafting materials, including autogenous bone, allografts, and xenografts.^{1–4}

Bone morphogenetic proteins (BMPs) comprise a family of osteoinductive proteins that are capable of stimulating existing host mesenchymal cells to form new bone. Discovered⁵ and named⁶ by Marshall Urist, and later purified and cloned,^{7–9} there are 15 to 20 known human BMPs today. At least 6 of them (BMP-2, BMP-4, BMP-5, BMP-6, BMP-7, and BMP-9) are osteoinductive. At present, only BMP-2 is available in the recombinant form and approved for sinus augmentation.

In 2007, recombinant human BMP-2 (rhBMP-2) became available for clinical applications in oral surgery. The autogenous bone replacement graft Infuse Bone Graft (Medtronic) has been approved for use in sinus augmentation and localized alveolar ridge augmentations associated with extraction sockets. It consists of

rhBMP-2 in a concentration of 1.5 mg/mL in combination with an absorbable collagen sponge (ACS; Heliostat). The total treatment dose used is determined by the number of sponges used, since there is a maximum dose that can be absorbed by the 1- × 3-inch ACSs provided.

A multicenter randomized controlled clinical dosing trial by Boyne et al¹⁰ and a 160-patient pivotal study by Triplett¹¹ have demonstrated positive results when Infuse Bone Graft is used for maxillary sinus augmentation. The cited studies, however, indicate that extensive sinus membrane elevation is required to place rhBMP-2/ACS grafts of sufficient volume. The results further indicate that considerable graft shrinkage occurs, low initial graft density is obtained, and that a high cost is involved when Infuse autogenous bone replacement graft is used as the sole grafting material for sinus augmentation.

The objectives of the following case reports were to determine an appropriate method of incorporating a mineralized bone replacement graft into the Infuse Bone Graft and to compare two different doses of this combination. The clinical and histologic results achieved following off-label use of the Infuse bone graft in combination with either a xenograft or allograft are presented. They propose a method to decrease graft shrinkage, improve graft density, and lower the cost of the procedure while still maintaining excellent vital bone formation.

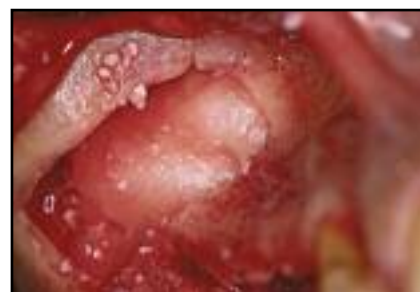Method and materials

Three patients with less than 4 mm of residual crestal bone requiring bilateral sinus augmentation for implant placement were treated in two private practice settings using the same surgical technique, with the only differences being the manner in which the sinuses were grafted. Informed consent was obtained, and three-dimensional imaging was performed prior to therapy for diagnostic purposes and to document the presurgical condition. All patients had healthy sinuses, were nonsmokers, and had no contraindications for sinus grafting procedures.

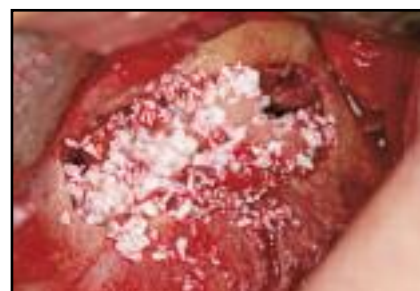After full-thickness mucoperiosteal flaps were raised to expose the lateral sinus wall, piezoelectric surgery was used to gain lateral entry to the sinus. Complete osteotomies were made and the lateral window bone was discarded. Initial sinus membrane release was accomplished with a piezoelectric elevator and then extended up the medial wall of the sinus with hand elevators. There were no observed perforations. Preparation of the rhBMP-2/ACS began approximately 30 minutes prior to the time it was needed clinically. This allowed for the mandatory 15 minutes of binding time of the rhBMP-2 to the collagen sponge. The sinuses were then grafted with Infuse bone replacement graft combined with a xenograft (patient 1) or an allograft (patients 2 and 3), as described in the following case reports. Barrier membranes were not used over the lateral window. Follow-up computed tomography (CT) scans were performed 1 week postoperatively (all patients), 3 months postoperatively



Figs 1a (left) and 1b (right) Collagen sponge with xenograft rolled into a cylinder and placed in the sinus.



Figs 1c (left) and 1d (right) Collagen sponge (cut) with xenograft as a composite and placed in the sinus.



(patient 1), and 6 months postoperatively (all patients).

Patient 1

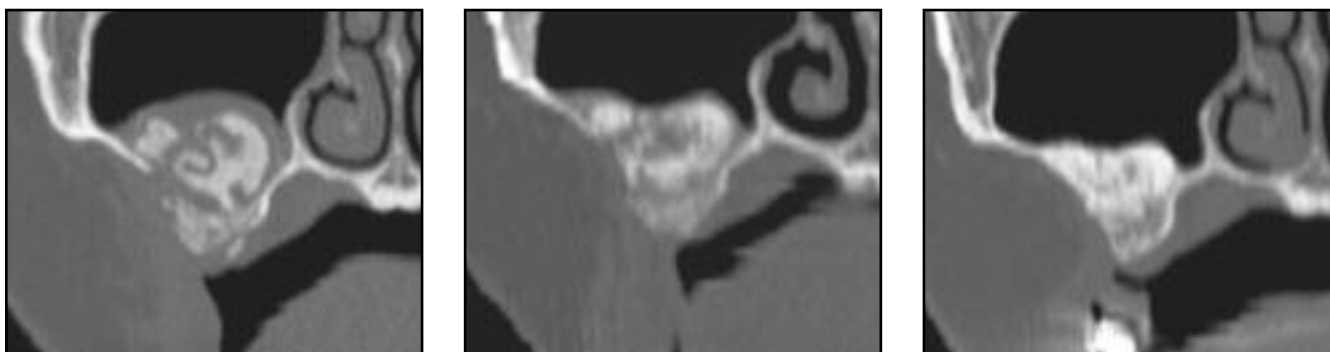
Treatment of this patient was planned to test two distinct methods for combining the Infuse Bone Graft at a concentration of 1.5 mg/mL/ACS with a xenograft (Bio-Oss, Osteohealth). Half of the particles were 0.5 to 1 mm and half were 1 to 2 mm. The right side was treated with three sponges that were coated with xenograft and then rolled into cylinders (Figs 1a and 1b). On the left side, the three sponges were cut into strips and mixed with the xenograft as a composite graft (Figs 1c and 1d). Note that the total volume of rhBMP-2 was the same on each side, and it was only the method of graft formulation that differed.

Patients 2 and 3

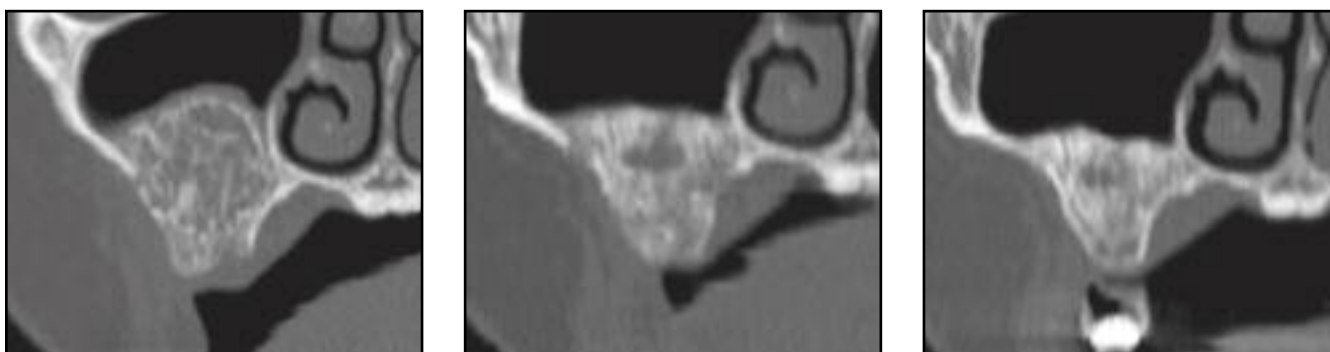
Treatment of these patients was planned to test two different volumes of Infuse Bone Graft at 1.5 mg/mL/ACS sponge in combination with a mineralized allograft (Allosource, Community Tissue Services) using the composite protocol from patient 1. Again, half of the particles were 0.5 to 1 mm and half were 1 to 2 mm. While the concentration of rhBMP-2 was the same for each sponge (1.5 mg/mL), the total volume of rhBMP-2/ACS on the four-sponge right side was twice that on the two-sponge left side (5.6 mL versus 2.8 mL). In patient 2, the sponges were loosely packed and in case 3 the collagen sponges were compressed after a 15-minute binding period to remove any excess water.

Follow-up

For patients 2 and 3, CT scans were taken within 1 week of surgery and 6 months following the grafting procedure. Histologic core specimens were obtained bilaterally on both patients at 6 months postsurgery. The 3- × 10-mm histologic specimens were harvested with a trephine drill from the superior distal aspect of the former lateral window. The cores were placed in neutral buffered formalin and sent to the Hard Tissue Research Laboratory, where the nondecalcified cores were prepared according to the cutting-grinding technique of Donath and Breuner¹² and Rohrer and Schubert.¹³ Histomorphometric analysis was performed as in previous papers from the current group of authors¹⁴ to determine percentages of vital bone, residual graft material,



Figs 1e to 1g Patient 1: Paraxial CT scans of the right sinus (cylindric technique) taken (left) immediately postsurgery, (center) 3 months postsurgery, and (right) 6 months postsurgery.



Figs 1h to 1j Patient 1: Paraxial CT scans of the left sinus (composite technique) taken (left) immediately postsurgery, (center) 3 months postsurgery, and (right) 6 months postsurgery.

and connective tissue and marrow. Measurements of gain in bone height were taken from identical paraxial views from CT scans taken 1 week after surgery and again after 6 months. Bone graft density recordings from the CT scans were obtained in Hounsfield units (HU).

For patient 1, CT scans were taken at 1 week, 3 months, and 6 months postoperative. The same bone gain height and density measurements taken for patients 2 and 3 were also taken for patient 1.

Results

Patient 1

Figures 1e to 1j present paraxial CT scan views of this bilateral situation grafted with Infuse Bone Graft and a xenograft in cylindric and composite configurations. Moderate shrinkage is evident in the interval from immediately postsurgery to 3 months. Shrinkage from 3 to 6 months occurred to a lesser degree. The initial density obtained with the composite technique was greater

Table 1 Patient 1: Graft density (HU) and crestal bone height (mm)				
	Density (right, cylindric)	Density (left, composite)	Height gain (cylindric)	Height gain (composite)
Immediately postsurgery	194	352	22.7	23.7
3 months postsurgery	452	705	17.8	19.4
6 months postsurgery	538	950	15.1	18.8

than that obtained with the cylinder technique (352 versus 194 HU). Final graft density was also greater (950 versus 538 HU) and the amount of graft shrinkage was less for the composite group (4.9 versus 7.6 mm). Table 1 lists graft density at three time intervals and crestal bone height gain at those same intervals.

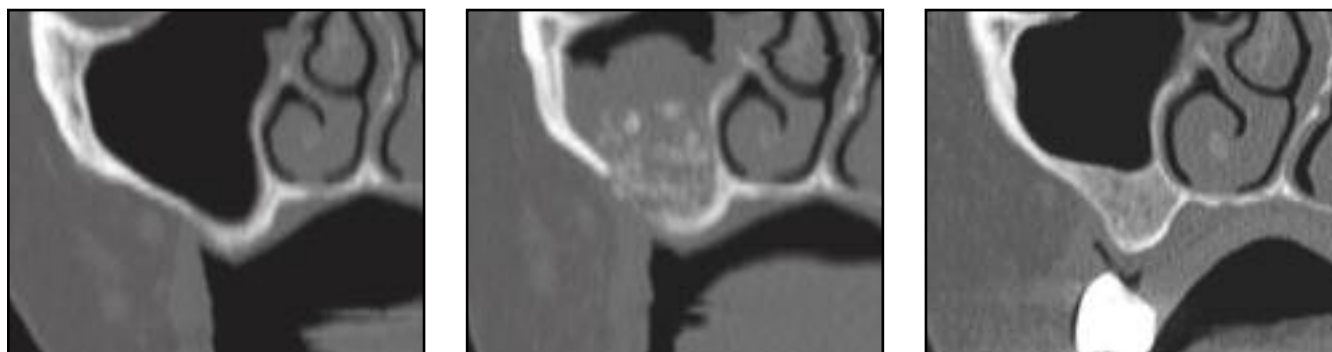
Patient 2

Figures 2a to 2f show representative paraxial views of a bilateral case grafted with Infuse Bone Graft and allograft in the four-sponge (Fig 2a to 2c, right side) and two-sponge (Fig 2d to 2f, left side) configurations. Extensive shrinkage and resorption occurred on both sides at 6 months. A higher initial density was achieved when fewer sponges (lower volume) were used to graft the sinus (315 versus 229 HU) and this increased density was maintained at 6 months (399 versus 295 HU). Shrinkage of the graft over the 6-month interval was much greater for the four-sponge graft than for the two-sponge graft (6 versus 2.4 mm) (Table 2).

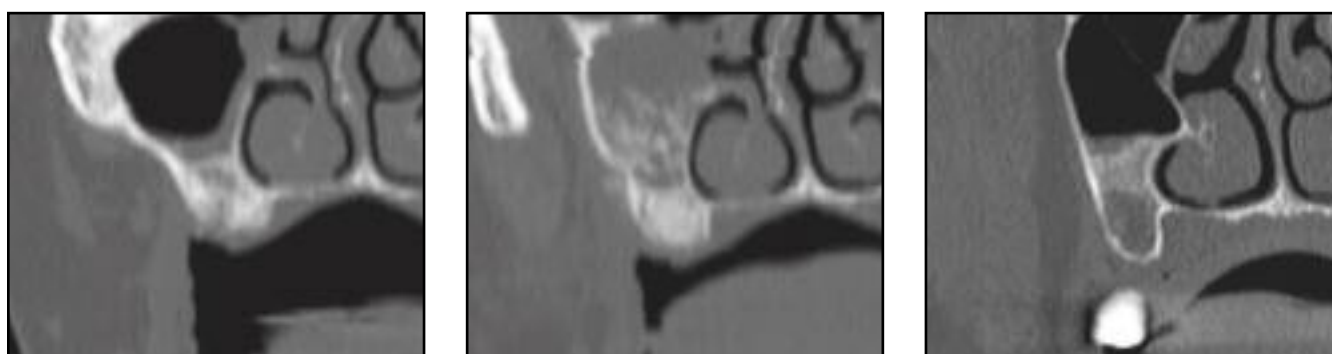
Figures 2g to 2l show representative histologic specimens from patient 2. Histologic specimens were similar on both sides, with the percentages of vital bone being 46% and 53% on the four- and two-sponge sides, respectively. Mature and immature vital bone dominated the mineralized portion of the sections. Numerous blood vessels were evident and many surfaces exhibited osteoblastic activity with osteoid formation. There was minimal evidence of the residual allograft.

Patient 3

In this patient, volumetric shrinkage was accurately measured using a computerized technique that three-dimensionally segments the sinus volume by variations in density, as measured in HU (Materialise Mimics version 12.11). This technique allowed for differentiation between the volume occupied by the bone graft and the extensive postoperative inflammatory response observed within the sinus. This inflammation had resolved by the 6-month postoperative scan

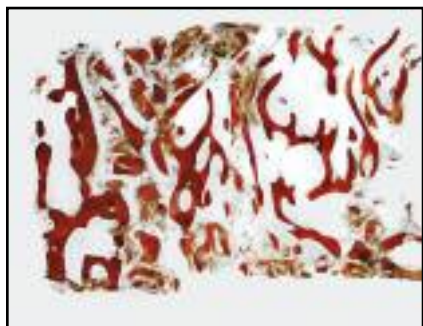


Figs 2a to 2c Patient 2: Paraxial CT scans of the right sinus (four sponges) taken (left) before surgery, (center) immediately postsurgery, and (right) 6 months postsurgery.



Figs 2d to 2f Patient 2: Paraxial CT scans of the left sinus (two sponges) taken (left) before surgery, (center) immediately postsurgery, and (right) 6 months postsurgery.

	Table 2 Patients 2 and 3: Graft density (HU) and bone height gain (mm)			
	Density (right, four-sponge)	Density (left, two-sponge)	Height gain (four-sponge)	Height gain (two-sponge)
Patient 2				
Immediately postsurgery	229	315	17.4	19.0
6 months postsurgery	295	399	11.4	16.6
Patient 3				
Immediately postsurgery	189	233.4	17.2	15.2
6 months postsurgery	213	185.7	12.4	13.6



Figs 2g and 2h Bone core from patient 2. Maturing vital bone with well-formed trabeculae and predominantly woven bone with surrounding connective tissue can be seen (Stevenel blue and van Gieson picro fuchsin; magnification [left] $\times 20$ and [right] $\times 40$).

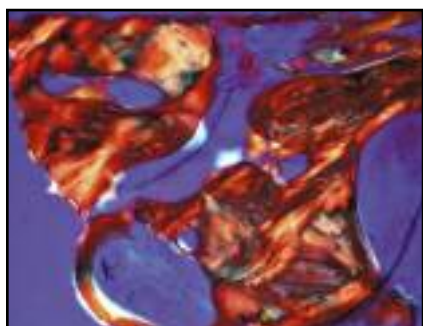
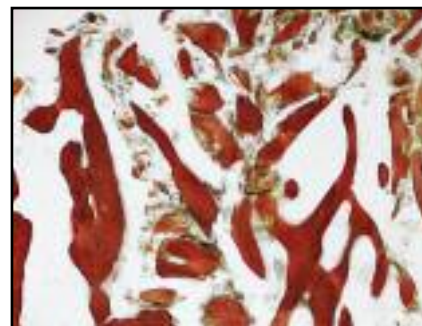


Fig 2i (left) Medium-power view of patient 2. Polarized view shows that most of the bone is lamellar and in various stages of mineralization (Stevenel blue and van Gieson picro fuchsin; magnification $\times 100$).

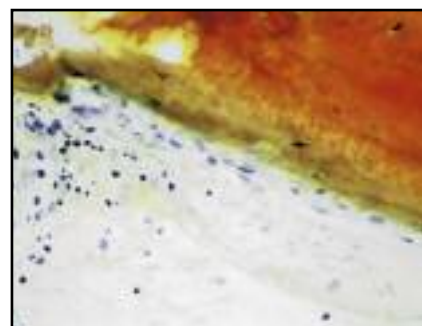


Fig 2j (left) High-power image shows the newly formed bone (red), osteoid (yellow/green), and surrounding osteoblasts (Stevenel blue and van Gieson picro fuchsin; magnification $\times 200$).

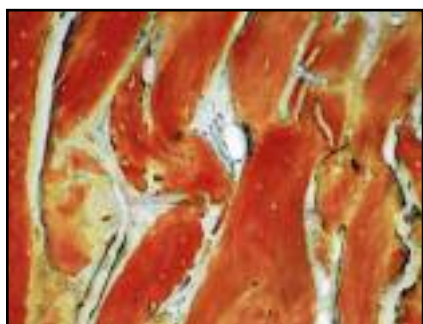


Fig 2k (left) Newly formed and mineralized vital bone with osteocytes visible in lacunae. Note the presence of multiple blood vessels (Stevenel blue and van Gieson picro fuchsin; magnification $\times 200$).

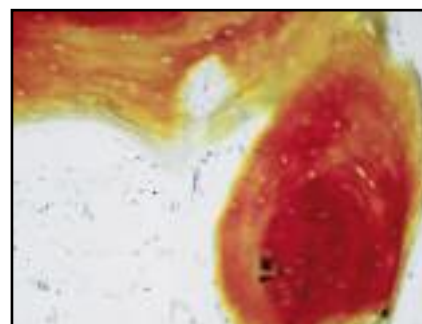
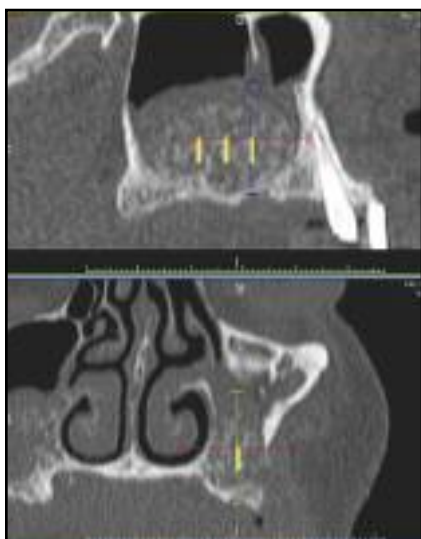


Fig 2l (right) Newly formed bone in various states of mineralization. Mostly mature bone (dark red), immature bone (light red), and osteoid (yellow) are present. Upper area depicts a rare finding of a remineralizing allograft particle (Stevenel blue and van Gieson picro fuchsin; magnification $\times 200$).

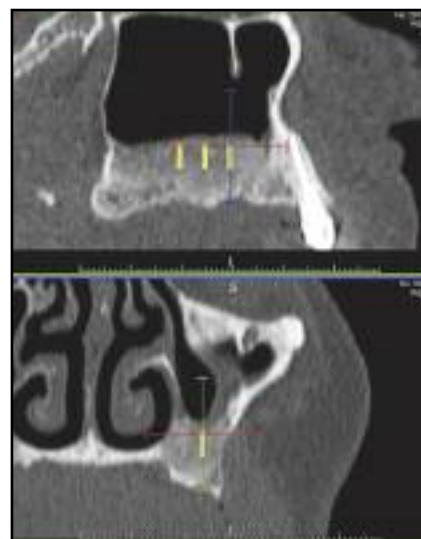
without intervention. The volumetric analysis revealed similar shrinkage on the four- and two-sponge sides (10.1% and 9.8%, respectively). The percentage of vital bone in these sinuses did not seem to be adversely affected by the compression process for the four- and two-sponge sides (36% and 45.5%, respectively). Figures 3a and

3b and 3c and 3d show the right and left sinuses, respectively, immediately after surgery and at 6 months postoperative. The density measurement "probes" can be seen in the graft. The density did not increase significantly over the 6-month time period as a result of complete resorption of the allograft.

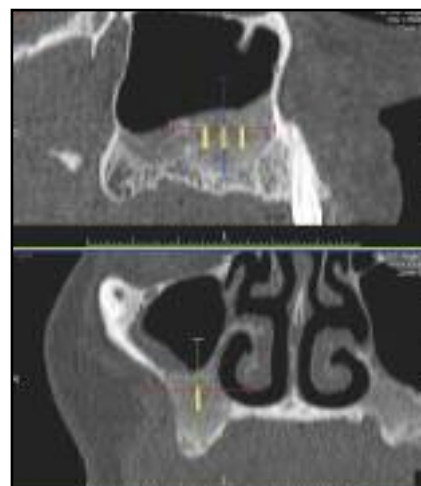
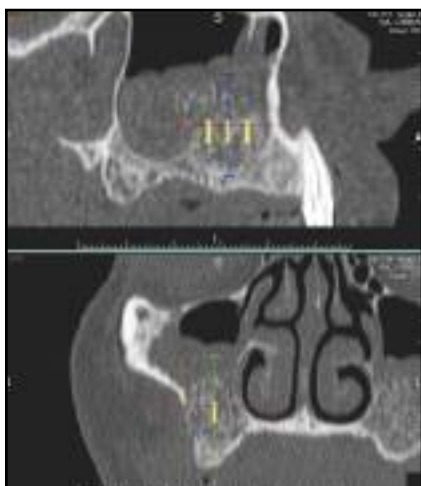
Table 2 lists graft densities at two time intervals postsurgery and the gain in bone heights at those same intervals for patients 2 and 3. The histomorphometric analysis for patients 2 and 3 is presented in Table 3.



Figs 3a and 3b Patient 3: CT scans of the right sinus (four sponges) taken (left) immediately postsurgery and (right) 6 months postsurgery. Note the loss of graft volume and the resolution of inflammation at 6 months.



Figs 3c and 3d Patient 3: CT scans of the left sinus (two sponges) taken (left) immediately postsurgery and (right) 6 months postsurgery. Note the loss of graft volume and the resolution of inflammation at 6 months.



Discussion

Other studies using rhBMP-2/ACS for sinus augmentation include one on its safety, efficacy, and clinical feasibility by Nevins et al in a goat model¹⁵; a pilot study in humans by Boyne et al on safety and efficacy¹⁶; and a randomized controlled clinical trial by Boyne et al.¹⁰ While the final outcome measure

of implant survival in the Boyne controlled trial was quite positive,¹⁰ the postoperative outcome with respect to bone formation requires additional consideration. While all patients but one formed new bone, 15% of cases did not have sufficient volume or density for timely implant placement. Further, the sinus augmentations in this study with Infuse Bone Graft as the

Table 3 Histomorphometric analysis (6 months) of Infuse Bone Graft + allograft for patients 2 and 3

	% vital bone	% residual graft	% marrow
Patient 2			
Right (four sponges)	46	0	54
Left (two sponges)	53	0	47
Patient 3			
Right (four sponges)	36	0	64
Left (two sponges)	46	0	55

sole grafting material used an average total dose of 8.9 mg (0.75 mg/mL cohort) and 20.8 mg (1.50 mg/mL cohort), with a total graft volume from the ACS sponges of 11.9 mL and 13.8 mL, respectively.

It is likely that the loss of graft volume and the early low density were related to the shrinkage, compression, or resorption of the collagen carrier material prior to the formation of new bone. This loss of volume may possibly be prevented by the addition of a supportive mineralized matrix. Further, it may be possible to increase both density and the rate of vital bone formation by the addition of an osteoconductive, mineralized matrix.

Xenografts, when used alone in sinus grafts, have been shown to maintain the height achieved at the time of graft placement and have also been shown to be highly osteoconductive.¹⁷ Similar but less well-documented results have been shown with mineralized allografts.¹⁸

The collagen sponge carrier cannot simply be removed and replaced with a mineralized bone replacement

graft since it is essential to the rhBMP-2 release dynamics and hence, its efficacy. If the rhBMP-2 is not allowed to bind to the sponge, it will quickly be eliminated via systemic circulation. The collagen sponge binds 95% of the rhBMP-2 to the site and allows it to be released over a 10- to 14-day period. Furthermore, this binding remains intact, even following rough handling of the collagen sponge upon placement.¹⁹

The shrinkage of these grafts resulting from resorption of the sponge must be taken into account at the time of graft placement. To insure that a sufficient volume of bone is formed, the graft must be placed higher than is ultimately required for implant placement.

In patient 1 of this study, the density observed in the immediate post-operative scan was a result only of the presence of the xenograft and was more consistent when the materials were mixed as a composite graft (left side). The increase in density at the 3- and 6-month intervals may have been due in part to new bone formation, but it is more likely greatly influenced

by the compression of the xenograft caused by the shrinkage and resorption of the sponges.

In patients 2 and 3, the right side used four sponges (5.6-mL volume) and the left used two sponges (2.8-mL volume). The left side had a greater allograft content than the right since the volume occupied by the sponges was less. In patient 2, the grafts on the four-sponge and the two-sponge sides had a similar volume in the immediate post-operative radiograph. At 6 months there was noticeable shrinkage on both sides, with that on the four-sponge side being much more extensive than on the two-sponge side. In patient 3, shrinkage was minimal (approximately 10%) and similar on both sides. The only difference between patients 2 and 3 was the compaction of the sponges at the time of grafting in patient 3. Both mature and immature vital bone was present, as was an extensive vascular network. The almost complete absence of residual allograft in both patients suggests an accelerated remodeling process or an rhBMP-2-mediated allograft resorption.

Conclusions

Given that these results come from only three patients, the following was observed:

- Graft shrinkage can still be expected with the addition of a xenograft or allograft.
- The composite technique resulted in greater density and less shrinkage than the cylinder technique.
- Shrinkage was less and density was greater with a xenograft as opposed to an allograft.
- Shrinkage appeared to be positively correlated with the number of sponges present.
- Shrinkage was less when the sponges were compressed after rhBMP-2 binding.
- Vital bone formation was similar with the two rhBMP-2/ACS volumes studied.

Further randomized controlled clinical trials are required to find protocols that increase graft density and promote the maintenance of graft volume while still generating acceptable quantities of vital bone. The effects of the added mineralized bone replacement grafts and the effects of the various volumes of rhBMP-2/ACS, combined with mineralized grafts on implant survival, are unknown at this time.

References

1. Wallace SS, Froum SJ. Effect of maxillary sinus augmentation on the survival of endosseous dental implants. A systematic review. *Ann Periodontol* 2003;8:328–343.
2. Del Fabbro, Testori T, Francetti L, Weinstein R. Systematic review of survival rates for implants placed in the grafted maxillary sinus. *Int J Periodontics Restorative Dent* 2004;24:565–577.
3. Aghaloo TL, Moy PK. Which hard tissue augmentation techniques are the most successful in furnishing bony support for implant placement? *Int J Oral Maxillofac Implants* 2007;22 suppl:49–70 [erratum 2008;23:56].
4. Pjetursson BE, Tan WC, Zwahlen M, Lang NP. A systematic review of the success of sinus floor elevation and survival of implants inserted in combination with sinus floor elevation. *J Clin Periodontol* 2008;35(8 suppl):216–240.
5. Urist MR. Bone: Formation by autoinduction. *Science* 1965;150:893–899.
6. Urist MR, Mikulski AJ, Nakagawa M, Yen K. A bone matrix calcification-initiator non-collagenous protein. *Am J Physiol* 1977; 232:C115–127.
7. Wang EA, Rosen V, Cordes P, et al. Purification and characterization of other distinct bone-inducing factors. *Proc Natl Acad Sci U S A* 1988;85:9489–9488.
8. Wang EA, Rosen V, D'Alessandro JS, et al. Recombinant human bone morphogenetic protein induces bone formation. *Proc Natl Acad Sci U S A* 1990;87:2220–2224.
9. Wozney JM, Rosen V, Celeste AJ, et al. Novel regulators of bone formation: Molecular clones and activities. *Science* 1988;242:1528–1534.
10. Boyne PJ, Lilly LC, Marx RE, et al. De novo bone induction by recombinant human bone morphogenetic protein-2 (rhBMP-2) in maxillary sinus floor augmentation. *J Oral Maxillofac Surg* 2005;63:1693–1707.
11. Triplett RG. Bone augmentation of the maxillary sinus floor with rh-BMP-2. In Lynch SE, Marx RE, Nevins M, Wisner-Lynch LA (eds). *Tissue Engineering*, ed 2. Chicago: Quintessence, 2008:186–202.

12. Donath K, Breuner G. A method for the study of undecalcified bones and teeth with attached soft tissues. The Säge-Schliff (sawing and grinding) technique. *J Oral Pathol* 1982;11:318–326.
13. Rohrer MD, Schubert CC. The cutting-grinding technique for histologic preparation of undecalcified bone and bone-anchored implants. Improvements in instrumentation and procedures. *Oral Surg Oral Med Oral Pathol* 1992;74:73–78.
14. Froum SJ, Tarnow DP, Wallace SS, Rohrer MD, Cho SC. Sinus floor elevation using anorganic bovine bone matrix (Osteo-Graf/N) with and without autogenous bone: A clinical, histologic, radiographic, and histomorphometric analysis—Part 2 of an ongoing prospective study. *Int J Periodontics Restorative Dent* 1998;18:528–543.
15. Nevins M, Kirker-Head C, Nevins M, Wozney JA, Palmer R, Graham D. Bone formation in the goat maxillary sinus induced by absorbable collagen sponge implants impregnated with recombinant human bone morphogenetic protein-2. *Int J Periodontics Restorative Dent* 1996;16:8–19.
16. Boyne PJ, Marx RE, Nevins M, et al. A feasibility study evaluating rhBMP-2/absorbable collagen sponge for maxillary sinus floor augmentation. *Int J Periodontics Restorative Dent* 1997;17:11–25.
17. Iezzi G, Scarano A, Mangano C, Cirotti B, Piattelli A. Histologic results from a human implant retrieved due to fracture 5 years after insertion in a sinus augmented with anorganic bovine bone. *J Periodontol* 2008;79:192–198.
18. Froum SJ, Wallace SS, Elian N, Cho SC, Tarnow DP. Comparison of mineralized cancellous bone allograft (Puros) to anorganic bovine bone matrix (Bio-Oss) for sinus augmentation: Histomorphometry at 26 to 32 weeks after grafting. *Int J Periodontics Restorative Dent* 2006;26:543–554.
19. Hsu HP, Zanella JM, Peckham SM, Spector M. Comparing ectopic bone growth induced by rhBMP-2 on an absorbable collagen sponge in rat and rabbit models. *J Orthop Res* 2006;24:1660–1669.